CASE REPORT

A Rare Case Report of Sirenomelia-the Mermaid Syndrome

Mukesh Mittal*, Apoorva Singh, Ashwini B, Dinesh Kumar**

ABSTRACT

Sirenomelia is a rare congenital fetal anomaly with characteristic feature of complete or partial fusion of lower limbs. It is commonly associated with renal agenesis, absent external genitalia, anorectal malformations, sacrococcygeal agenesis, single umbilical artery and oligohydramnios. Here, we report a rare case of antenatal detection of sirenomelia at 33 weeks of gestation with associated anomalies.

Key-words: Mermaid syndrome, Sirenomelia, oligohydramnios, single umbilical artery

Key Messages: Sirenomelia is a rare congenital anomaly involving fusion of lower limbs associated with severe oligohydramnios, renal agenesis and single umbilical artery.

INTRODUCTION

Sirenomelia, also known as mermaid syndrome due to its resemblance to mermaid in Greek mythology. It is a rare congenital structural anomaly with its incidence being 2-3 cases per 1 lacs births with male and female ratio of 3:1. About 300 cases have been reported worldwide of which 8 are from India[1]. Key feature of sirenomelia is single or fused lower limbs which can be associated with other severe anomalies like bilateral renal agenesis, agenesis of external genitalia and anorectal atresia. Most of the cases are incompatible with life.

CASE HISTORY

A 24 years old primigravida with 33 weeks of gestation presented for the first time to our hospital and was referred to us for USG. Her personal and family history was unremarkable. She was of low socio-economic status. There was no history of any medication/infections in early period of pregnancy. No history of consanguineous marriage.

Antenatal USG (Figure 1) showed breech presentation with severe oligohydramnios. Fetal kidneys and bladder were not visualised. There was a single lower limb with single femur and single short bone below knee likely tibia. (Figure 2) There was a hypoechoic lesion in fetal pelvis with calcification and lower fetal spine was not visualised. Due to severe oligohydramnios characterisation of mass was not possible. Because of presence of calcifications within the mass, the probable diagnosis was meconium pseudocyst. Single umbilical artery was found. Examination of brain and heart was normal.

3D USG was done which showed a single short lower extremity with absence of foot confirmed our diagnosis. (Figure 3)

The lady delivered a newborn of 2.1kg at 36 weeks of gestation via normal vaginal delivery. Neonate was still born. Physical examination of newborn showed single lower extremity with absence of foot, absence of external genitalia, anal opening and single umbilical artery (Figure 4). Autopsy and radiograph of the newborn was denied by the parents. Intrapartum and postpartum period of mother was uneventful.

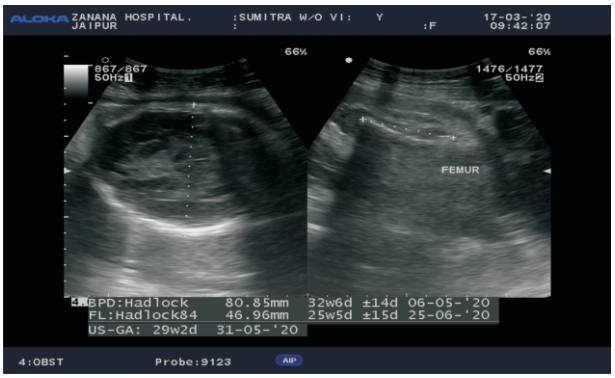

Figure 1: USG showing fetus of gestational age 33 weeks with small single femur.

*Associate Professor, **Junior Resident
Department of Radio diagnosis, SMS Medical College, Jaipur.
Contributor Author:
Dr Apoorva Singh
Junior Resident, Department of Radiodiagnosis, SMS Medical College, Jaipur.
Email- apoorva.singh.247@gmail.com
Mobile No. 9916391925

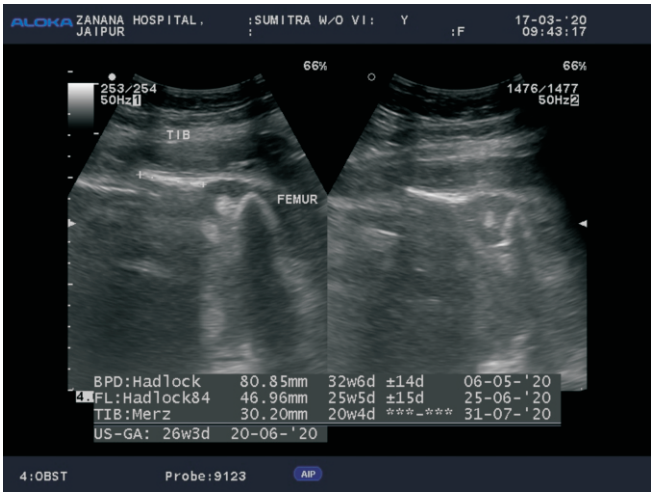

Figure 2: USG showing single lower limb with single short tibia.

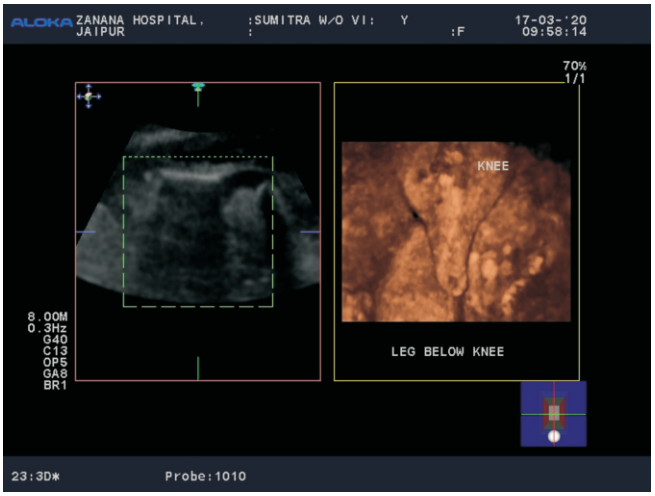

Figure 3: 3D USG showing blind ending single short lower extremity with absence of foot.

Figure 4: Fetus showing single lower extremity and absence of foot suggestive of sirenomelia.

DISCUSSION

Sirenomelia, also known as sirenomelia sequence, is a severe malformation of the lower body characterized by fusion of the legs and a variable combination of visceral abnormalities. Owing to visceral abnormalities, sirenomelia is usually incompatible with life[2]. Sirenomelia can be a part of caudal regression sequence and VATER association[3].

Most cases occur for non-apparent reasons, as seen in this case. However, maternal diabetes mellitus[4], genetic predisposition, environmental factors (tobacco use, retinoic acid and heavy metal exposure), and vascular steal phenomenon with the single vitelline umbilical artery diverting blood supply and nutrients from the lower body and limbs have been reported as possible etiological factors[5-8].

Sirenomelia can be diagnosed as early as 13 weeks by using high resolution or colour Doppler sonography. Foetal MRI can also help in diagnosis. Oligohydraminos acts as an alerting sign[9]. Sirenomelia has been classified into 7 types by Stocker and Heifetz[10].

TYPE	CHARACTERSTICS
I	All thigh and leg bones are present
II	Single fibula
III	Absent fibula
IV	Partially fused femurs, fused fibula
V	Partially fused femurs
VI	Single femur, single tibia
VII	Single femur, absent tibia

According to this classification this case belonged to type VI.

3D ultrasound can be a potential tool in diagnosing this condition.

Sirenomelia is a fatal condition and can be detected at an early gestation on ultrasound, pregnancy can be terminated to prevent high risk pregnancy and maternal stress.

REFERENCES:

1. Taori K B, Mitra K, Ghonga N P, Gandhi R O, Mammen T, Sahu J. Sirenomelia sequence (mermaid) : Report of three cases. Indian J Radiol Imaging 2002;12:399-401
2. Garrido-Allepuz C, Haro E, Gonzalez-Lamuno D, et al. : A clinical and experimental overview of sirenomelia: insight into the mechanisms of congenital limb malformations. Dis Model Mech. 2011;4(3):289–99 10.1242/dmm.007732

3. Tanigasalam V, Gowda M, Plakkal N, Adhisivam B, Vishnu Bhat B. Sirenomelia with VACTERL association-a rare anomaly. Pediatr Neonatol. 2018;59(4):410–1.
4. Assimakopoulos E, Athanasiadis A, Zafrakas M, Dragoumis K, Bontis J. Caudal regression syndrome and sirenomelia in only one twin in two diabetic pregnancies. Clin Exp Obstet Gynecol. 2004;31:151–3.
5. Kavunga, E.K., Bunduki, G.K., Mumbere, M. et al. Sirenomelia associated with an anterior abdominal wall defect: a case report. J Med Case Reports 13, 213 (2019).
6. Valenzano M, Paoletti R, Rossi A, Farinini D, Garlaschi G, Fulcheri E. Sirenomelia: pathological features, antenatal ultrasonographic clues, and a review of current embryogenic theories. Hum Reprod Update. 1999;5:82–6
7. Stevenson RE, Jones KL, Phelan MC, Jones MC, Barr M Jr, Clericuzio C. Vascular steal: the pathogenetic mechanism producing sirenomelia and associated defects of the viscera and soft tissues. Pediatrics. 1986;78:451–7.
8. Twickler D, Budorick N, Pretorius D, Grafe M, Currarino G. Caudal regression versus sirenomelia: sonographic clues. J Ultrasound Med. 1993;12(6):323–30.
9. Sonal Prasad, J Anupama. Rare case report of sirenomelia: the mermaid baby. International Journal of Contemporary Medical Research 2017;4(12):1-3.
10. Stocker JT, Heifetz SA. Sirenomelia. A morphological study of 33 cases and review of the literature. Perspectives in Pediatric Pathology. 1987 ;10:7-50